

Comparison of Transthecal Approach with Traditional Conservative Approach for Primary Closure After Incidental Durotomy in Anterior Lumbar Tear

Mohammadreza Shahmohammadi MD¹, Melika Hajimohammadebrahim-Ketabforoush MSc²,
Faranak Behnaz MD³, Ehsan keykhosravi MD⁴, Sara Zandpazandi MD⁵

¹ Shohada Tajrish Comprehensive Neurosurgical Center of Excellence, Functional Neurosurgery Research Center, Shohada Tajrish Hospital, Shahid Beheshti University of Medical Sciences, Tehran, Iran.

² Department of Clinical Nutrition and Dietetics, Faculty of Nutrition Sciences and Food Technology, National Nutrition and Food Technology Research Institute, Shahid Beheshti University of Medical Sciences, Tehran, Iran.

³ Assistant Professor of Anesthesiology Department Shahid Beheshti University of Medical Science, Tehran, Iran.

⁴ Department of neurosurgery, faculty of medicine, Mashhad University of Medical Sciences, Mashhad, Iran.

⁵ Medical Intern, Neurosurgery Researcher, Functional Neurosurgery and Stereotaxi Research Center Shohada Tajrish Neurosurgical Comprehensive Center of Excellence, Shohada Tajrish Hospital, Shahid Beheshti University of Medical Sciences, Tehran, Iran.

Corresponding author: Mohammadreza Shahmohammadi, e-mail: dr_mr11@yahoo.com

Address: Tajrish Sq., Tehran, I.R. Iran

Zip Code: 1979814436

Tel: +98(21)22718001

Fax: +98(21) 22719013

Short title: Transthecal versus Conservative Approach in Management of Incidental Durotomy

Funding: This research did not receive any specific grant from funding agencies in the public, commercial, or not-for-profit sectors.

Conflicts of Interest: None of the authors had any personal or financial conflicts of interest.

Abstract

Objective: This study aimed to compare the transthecal approach with the conservative approach for primary closure after durotomy in anterior lumbar dural tear. The study also intended to assess the efficacy of the transthecal approach to decrease postsurgical complications and costs.

Materials and Methods: A total of 21 patients undergoing L2-S1 laminectomy with anterior incidental durotomy were randomly divided into a transthecal group (n=9) and a conservative group (n=12) based on the surgical dural closure technique. Postoperative pseudomeningocele, wound infection, rootlet herniation, pneumocephalus, CSF leakage, headache, meningitis, in addition to surgery duration and length of hospitalization, were examined and compared in the both groups.

Results: The frequency of pseudomeningocele and CSF leakage in patients undergoing the transthecal approach was significantly lower than those undergoing the conservative approach (P=0.045 and P=0.008, respectively). Furthermore, although, the differences in the frequency of meningitis, pneumocephalus, headache, and wound infection were not statistically significant between the two groups, the effect size of the comparison was obtained 49.4, 19.8, 7.1, and 2.6, respectively. This indicated that the differences were clinically significant between the two groups.

Conclusions: We found that the both approaches of dural closure, whether dural repair with the transthecal technique or the traditional conservative treatment, were safe. However, the transthecal

approach was significantly more successful in managing CSF leakage as well as its complications and clinical outcomes.

Keywords: Incidental durotomy, transthecal approach, CSF leakage, postsurgical complications

Introduction

Incidental durotomy (ID) or dural tear is a frequent complication of spinal surgeries, occurring in 4–17% of decompressive spinal surgeries¹. It has an incident rate of 1.8-17.4% in lumbar surgeries, and generally, 1-17% in spinal surgeries, depending on complications of the operation^{2, 3}. Risk factors for ID during surgery are old age, revision surgery, minimally invasive surgery, number of instrumented segments, the surgeon's experience, female sex, preexisting conditions (degenerative spondylolisthesis), ossification of the longitudinal ligament, and synovial cysts^{2, 4-10}. IDs are mostly posterior or lateral, occurring during thecal sac manipulation to perform decompression. Anterior IDs are rare in the posterior spine surgery approach, and because of their small size, they can tamponade themselves against the vertebral body, especially in minimally invasive surgeries^{10, 11}. Large IDs need primary repair as they may lead to severe complications and morbidities such as severe headache and posture related headache, pseudomeningocele formation, nerve root entrapment, arachnoiditis, intracranial hemorrhage, durocutaneous fistula, photophobia, dizziness, cranial nerve palsy, need for reoperation, increased administration of antibiotics, significantly prolonged bed rest, and hospital stay^{2, 5, 10, 12-15}. Cases of anterior ID cannot be managed by routine primary repair, and no definitive treatment has been proposed for such cases. Many studies have reported good results after the surgical repair of durotomies^{13, 16, 17}. However, no clinical study has compared the two surgery approaches. In the present study, we reported the use of the transthecal approach described by Nakhla et al.¹⁰ for the repair of anterior dural tear occurring in the posterior spinal approach through a dorsal durotomy compared to the conservative approach in patients with

lumbar spinal surgery. We also assessed the efficacy of this novel approach (transthecal) to decrease postsurgical complications and costs.

Materials and methods

The present parallel clinical trial was conducted in a single-blind manner on 21 patients undergoing L2-S1 laminectomy, who experienced iatrogenic anterior dural tear due to either a surgical procedure or a vertebral fracture, from December 2017 to February 2020 at the Shohadae Tajrish Hospital, Tehran, Iran. Patients who could not undergo primary dural repair (by suturing the tear) using the conventional posterolateral approach and also were under 70 years of age without any major comorbidities (e.g., cardiac, renal, and lung diseases) were included in the study. The exclusion criteria were simultaneous participation in another clinical trial, unwillingness to continue participation, hypercoagulopathy, history of lumbar spinal surgery, severe reactions to conventional medications, and increased intracranial pressure (ICP) due to intracranial pathologies. All the patients signed informed consent. Since anterior dural tear is an extremely rare event, and to our knowledge, no study has compared the transthecal route with other approaches for primary closure after durotomy in anterior lumbar tear, it was not possible to calculate the true power of the transthecal approach. Therefore, we carried out a small pilot study to obtain estimations for properly calculating the sample size. Based on the surgical dural closure technique, the patients were randomly divided into two groups: in group one (undergoing the transthecal approach), after the assessment of the anterior duratomy, proximal and distal areas of dural tear were determined. Then, incision was made on the same site on the posterior dura. The dura was then opened under a microscope, rootlets were gently pushed to the right and left using a piece of cotton, and the dural tear was repaired using prolene 6-0 with locked continuous suture. Any

possible defect at the site of anterior dural tear was repaired using muscle fascia. After the full closure of the dural defect and removal of the cotton, the rootlets were rinsed with saline and returned to their original position. Dorsal dura was also repaired under a microscope using prolene 4-0. After these stages, a hemovac drain was inserted under the muscle fascia, and the fascia was completely sutured (water-tight) using vicryl 1-0. Routine procedures were then applied for cutaneous and subcutaneous repair. Once the primary dural tear repair was assured, possible CSF leak was tested using Valsalva maneuver. In the group two (undergoing the conservative approach), conventional dural repair was also not possible, and CSF leak was prevented by covering the dorsal and dorsolateral region of the dura (between the rootlets above and below the tear site) with a 2×2 cm on-lay pad of fat taken from subcutaneous tissue and administration of fibrin glue over and around the pad. As in the group one, hemovac drain was inserted under the muscle fascia, and also, subcutaneous and cutaneous were routinely repaired by suturing. The primary surgery was open for all the patients. Moreover, in case of anterior ID during the surgery in patients with degenerative disease or the occurrence of anterior ID in spinal traumas, primary dural tear treatment (transthecal closure or the conservative method) was also performed. In the both groups, hemovac drain was maintained for at least 72 hours (during which the patients were RBR). All the patients received a first generation cephalosporin as prophylaxis. In the both groups, hemovac drain was removed after 72 hours if the drain function was less than 20 cc/12 hours, and its site was sutured. An acetazolamide tablet (dosage adjusted by patient weight) was administered in the both groups. Intermittent pneumatic compression was used to prevent deep venous thrombosis (DVT). The pre-operative body mass index (BMI) was calculated via dividing the body weight (kg) by the height squared (m²) for all the patients. Other medical information required was also extracted through medical records. The patients were followed up for one month after the

surgery. During this period, all the patients underwent lumbosacral MRI to assess the surgical site for pseudomeningocele, wound infection, and rootlet herniation. During the first 21 days after the surgery, all the patients underwent brain CT scan for possible postoperative pneumocephalus. The patients were also monitored for CSF leakage, headache, meningitis, surgery duration, and length of hospitalization (LOH).

Statistical Analysis

The data were analyzed using the statistical package IBM SPSS, version 22.0 (Statistical Package for the Social Sciences, IBM Corp., Armonk, New York, USA). The Kolmogorov-Smirnov test was used to assess the data distribution normality. To compare the two groups, statistical tests including independent t-test (for comparison of the mean age, BMI, and surgery duration), the Mann-Whitney U test (for comparison of the LOH), and Fisher's exact test for qualitative variables were performed. All the tests were performed at 5% level.

Results

A total of 30 patients were randomly divided into transthecal and conservative groups. Three and six patients were excluded from the transthecal and conservative groups, respectively, because they were not eligible to continue the study. Finally, nine patients in the transthecal group and 12 patients in the conservative group completed the study. Figure 1 illustrates how this placement was performed for the patients throughout the study. Some basic and medical information of the patients is summarized in Table 1. As shown in Table 1, there was no significant difference in terms of age and sex between the two groups. In addition, there were three (33.3%) patients with fracture, one (11.1%) patient with discopathy, and five (55.6%) patients with lumbar spinal canal stenosis in the transthecal group. These values were 3 (25.0%), 1 (8.3%), and 8 (66.7%) in the

conservative group, respectively. This means that the two groups were not significantly different in this respect. This was also true for smoking and BMI. Postoperative complications that were compared in the present study included pseudomeningocele, wound infection, pneumocephalus, CSF leakage, headache, and meningitis (Table 2). Furthermore, the frequency of pseudomeningocele and CSF leakage in patients undergoing the transthecal approach was significantly lower than those undergoing the conservative approach ($P=0.045$, $P=0.008$, respectively). The proportion of meningitis to both the transthecal and conservative approaches was estimated to be 0.0% and 33.3%, respectively. However, there was no statistically significant difference between the two groups ($P=0.104$), but the effect size obtained for the comparison was 49.4, indicating that the difference between the two groups was “large” clinically. The same is true for pneumocephalus, headache, and infections with the effect sizes of 19.8, 7.1, and 2.6. This means that although p-value tests did not show any significant difference between the two groups, the effect size indicated a large clinical difference between the two groups by pneumocephalus and headache, and also, a medium clinical difference by infections. Figure 2 depicts the comparison of these postoperative complications between the two groups. On the other hand, although the duration of the surgery was higher in patients undergoing the transthecal approach, the length of hospital stay for these patients was significantly reduced (Figure 3).

Discussion

The purpose of the present study was to compare the transthecal approach with the conservative approach for primary closure after durotomy in anterior lumbar dural tear. The study also aimed to assess the efficacy of the transthecal approach to decrease postsurgical complications and costs. Our findings indicated that microscopic transthecal ventral dural repair was significantly effective in preventing pseudomeningocele and CSF leakage, as compared with the conservative approach.

Furthermore, some complications such as meningitis, pneumocephalus, headache, and wound infection occurred less frequently under the transthecal approach compared to the conservative approach; the differences were appeared to be clinically significant. Moreover, the transthecal approach was able to significantly reduce LOH. The timely diagnosis and primary repair of anterior IDs are critical to prevent CSF leakage complications and clinical outcomes. It is especially important to consider that, due to the rare occurrence of anterior IDs, the best repair approach is not known yet. Various techniques such as the use of fibrin glue, gel foam, and fat patch with or without suturing have been reported in previous studies^{3, 11, 18-21}, and only a few reports recommended the direct repair of ventral durotomy using the transthecal approach^{10, 22, 23}. In our knowledge, no study compared the transthecal approach with the conservative route to anterior ID repair in a clinical trial design. Therefore, here, the existing literature including case reports, case series, and descriptive or cohort studies was discussed. The transthecal technique by details was first introduced for repair an anterior dural tear in a patient undergoing posterior lumbar interbody fusion (PLIF) by minimally invasive spine surgery (MISS) by Nakhla et al.¹⁰ (2017). Since primary dural closure was not possible, the site received conventional repair using a fat patch and by the administration of fibrin glue. Due to persistent CSF leak and its complications (delayed wound healing and postural headache), the patient underwent an open spine surgery (OSS) nine days later, and received microscopic anterior dural repair using the transthecal approach. Then, the symptoms were improved. Although anterior IDs, and consequently, CSF leakage during MISS can be less likely to occur²⁴, due to the limited field of view in such endoscopic surgery, dural repair is not possible in the transthecal approach at the same time. Consistent with the mentioned case study report¹⁰, in our clinical trial with a larger sample size, we showed that the transthecal approach through OSS was much more effective than the conservative treatment to diminish CSF

leakage and its complications. Earlier, Choi et al.²² in their case series study reported that all the four patients undergoing lumbar surgery developed the undetected intraoperative anterior ID. None of them had the postoperative CSF leakage and its complications; however, their main complaint was a severely persistent radicular pain in the legs a few days after the surgery. Postoperative MRI confirmed anterior IDs and showed transdural nerve rootlet entrapment. After using the transthecal approach to reposition the herniated rootlet and dural repair in reoperation, the radicular pain symptom disappeared. In our study two patients who were included in the conservative group suffered from refractory severe radicular pain after the primary surgery. They had a rootlet herniation in the intervertebral disc space that was confirmed by follow up MRI. They were excluded from the study because they underwent another surgery for repositioning the herniated rootlet and dural repair. Therefore, it is very important to detect and repair an anterior ID during the first surgery for preventing neural elements herniation and its complications. Another study found that the use of the posterior transthecal approach was effective and safe in five patients with a thoracolumbar fracture²³. Their study is an example for this claim that the type of disease pathology that requires spine surgery cannot affect the advantages of the transthecal approach. As the findings of their study showed, all the five patients with fractures and neurological defects successfully received the transthecal approach for dural lacerations repair. Furthermore, compressive bony elements were removed, and the deformity was corrected without any surgical complications resulting from CSF leakage²³. In the present study, we also had trauma cases, and the transthecal approach was successfully applied in them as well. In addition, most surgeons have recommended primary closure by suturing with or without fibrin glue for treatment of IDs in the posterior and posterolateral region of dura. The use of muscle or fat patch with or without additional closure aids such as fibrin glue, Surgicel and DuraGen have also been

recommended (almost when direct suturing is not possible)^{3, 17, 25-27}. In another study, there was no significant difference between various dural closure techniques in terms of the effect on the rate of revision surgery due to CSF leakage and its complications³. It is worth mentioning that although the investigation of the revision surgery rate was not the end point of our study, along with the main findings of the present study, we found that two out of 12 patients undergoing the conservative approach needed the revision surgery 11 to 13 days after the primary surgery due to persistent CSF leakage, while no patient in the transthecal group had such a need. Our work in the literature that has seldom examined anterior IDs was the first study with a parallel clinical trial design, which compared the novel transthecal approach with the traditional conservative approach for repairing anterior IDs. All of our patients underwent OSS, and the diagnosis of IDs and its repair were made simultaneously as the first surgery. In our study, there were no fatal complications such as fulminant meningitis, tension pneumocephalus causing neurologic deficit, death, and DVT in the both group. This study is consistent with most previous studies^{3, 10}, showing that the both treatment methods were effective in controlling fatal complications. However, our study had also some limitations, including a small sample size. In addition, we did not examine patients for ASA scores prior to the surgery. Although there were no clinical neurologic deficits observed in our patients, neuromonitoring during the repair and movement of rootlets in the transthecal technique can help reduce and prevent potential complications. Since anterior ID is particularly rare and has not been mentioned widely in studies, future clinical studies with a larger sample size will make accurate comparisons more possible.

Conclusions

The occurrence of anterior IDs is highly rare during spine surgeries. We realized that the both approaches of dural closure, whether dural repair with the transthecal technique or the traditional

conservative treatment, were safe. However, the transthecal approach was significantly more successful in managing CSF leakage as well as its complications and clinical outcomes. Further clinical trials with higher sample sizes are needed to substantiate this claim.

Author contributions

M.S. conceptualized and designed the study; M.S. and M.H. analyzed data and wrote the manuscript; M.S, F.B, E.K. and S.Z. collected data; BMI data was calculated by M.H.; M.S. and M.H. interpreted the data; M.S. critically revised the manuscript for intellectual content and data accuracy; M.S. had responsibility for final content. All of the authors read and approved the final manuscript.

References

1. Farshad M, Aichmair A, Wanivenhaus F, Betz M, Spirig J, Bauer DE. No benefit of early versus late ambulation after incidental durotomy in lumbar spine surgery: a randomized controlled trial. *Eur. Spine J.* 2019; 29:141-146.
2. Chen Z, Shao P, Sun Q, Zhao D. Risk Factors for Incidental Durotomy During Lumbar Surgery: A Retrospective Study by Multivariate Analysis. *Clin Neurol Neurosurg.* 2015; 130:101-104.
3. Kamenova M, Leu S, Mariani L, Shaeren S, Soleman J. Management of Incidental Dural Tear During Lumbar Spine Surgery. To Suture or Not to Suture? *World Neurosurg.* 2016; 87:455-462.
4. Herren C, Sobottke R, Mannion AF, et al. Incidental durotomy in decompression for lumbar spinal stenosis: incidence, risk factors and effect on outcomes in the Spine Tango registry. *Eur Spine J.* 2017; 26: 2483-2495.

5. Enders F, Ackemann A, Müller S, Kiening K, Orakcioglu B. Risk Factors and Management of Incidental Durotomy in Lumbar Interbody Fusion Surgery. *Clin Spine Surg.* 2018;31:127–131.
6. Buck JS, Yoon ST. The incidence of durotomy and its clinical and economic impact in primary, short-segment lumbar fusion: an analysis of 17,232 cases. *Spine (Phila Pa 1976).* 2015;40:1444–1450.
7. Stolke D, Sollmann WP, Seifert V. Intra- and postoperative complications in lumbar disc surgery. *Spine (Phila Pa 1976).* 1989; 14:56–59.
8. Haller JM, Calvert G, Spiker WR, Brodke DS, Lawrence BD. Remote cerebellar hemorrhage after revision lumbar spine surgery. *Global Spine J.* 2015;5:535–537.
9. McMahon P, Dididze M, Levi AD. Incidental durotomy after spinal surgery: a prospective study in an academic institution. *J Neurosurg Spine.* 2012;17:30–36.
10. Nakhla J, Nasser R, de la Garza Ramos R, et al. Anterior Lumbar Dural Tear: A Transthecal Route for Primary Closure after Iatrogenic Durotomy. *World Neurosurg.* 2017; 107: 522-525.
11. Than KD, Wang AC, Etame AB, La Marca F, Park P. Postoperative Management of Incidental Durotomy in Minimally Invasive Lumbar Spinal Surgery. *Minim Invasive Neurosurg.* 2008; 51: 263-266.
12. Saxler G, Krämer J, Barden B, Kurt A, Pförtner J, Bernsmann K. The Long-term Clinical Sequelae of Incidental Durotomy in Lumbar Disc Surgery. *Spine (Phila Pa 1976).* 2005;30: 2298-2302.
13. Ishikura H, Ogihara S, Oka H, et al. Risk factors for incidental durotomy during posterior open spine surgery for degenerative diseases in adults: A multicenter observational study.

- PLoS One. 2017; 12 (11), e0188038.
14. Dafford EE, Anderson PA. Comparison of dural repair techniques. *Spine J.* 2015;15:1099-1105.
 15. Wichmanna TO, Karabegovic S, Rasmussena MM. Cranial nerve palsies due to incidental durotomy in lumbar Spine surgery: a case report. *Br J Neurosurg.* 2018; DOI: 10.1080/02688697.2018.1508642.
 16. Finnegan WJ, Fenlin JM, Marvel JP, Nardini RJ, Rothman RH. Results of surgical intervention in the symptomatic multiply-operated back patient: analysis of sixty-seven cases followed for three to seven years. *J Bone Joint Surg Am.* 1979; 61;1077–1082.
 17. Cammisa Jr FP, Girardi FP, Sangani PK, Parvataneni HK, Cadag S, Sandhu HS. Incidental Durotomy in Spine Surgery. *Spine (Phila Pa 1976).* 2000; 25:2663–2667.
 18. Tafazal SI, Sell PJ. Incidental durotomy in lumbar spine surgery: incidence and management. *Eur Spine J.* 2005;14:287-290.
 19. Weng YJ, Cheng CC, Li YY, Huang TJ, Hsu RW. Management of giant pseudomeningoceles after spinal surgery. *BMC Musculoskelet Disord.* 2010;11:53.
 20. McMahon P, Dididze M, Levi AD. Incidental durotomy after spinal surgery: a prospective study in an academic institution. *J Neurosurg Spine.* 2012; 17:30-36.
 21. Tsutsumimoto T, Yui M, Uehara M, Ohta H, Kosaku H, Misawa H. A prospective study of the incidence and outcomes of incidental dural tears in microendoscopic lumbar decompressive surgery. *Bone Joint J.* 2014;96-B:641-645.
 22. Choi JH, Kim JS, Jang JS, Lee DY. Transdural Nerve Rootlet Entrapment in the Intervertebral Disc Space through Minimal Dural Tear: Report of 4 Cases. *J Korean Neurosurg Soc.* 2013; 53: 52–56.

23. Huang AP, Chen CM, Lai HS, et al. Posterior transthecal approach for repair of cauda equina fibers and ventral dural laceration in lumbar burst fracture: a novel surgical technique. *Spine (Phila Pa 1976)*. 2013; 38:E1156-61.
24. AG Kulkarni. Are Dural Tears in Minimal Invasive Spine Surgery of the Lumbar Spine More Forgiving than in Open Spine Surgery? *Spine journal*.2014;11:S105.
25. Brookfield K, Randolph J, Eismont F, Brown M. Delayed symptoms of cerebrospinal fluid leak following lumbar decompression. *Orthopaedics*. 2008; 31:816.
26. Bosacco SJ, Gardner BA, Guille JT. Evaluation and treatment of dural tears in lumbar spine surgery. *Clin Orthop Relat Res*. 2001; 389:238–247.
27. Narotam PK, Jose S, Nathoo N, Taylon C, Vora Y. Collagen matrix (DuraGen) in dural repair: analysis of a new modified technique. *Spine*. 2004;29:2861–2867.

Table 1. Basic characteristics and medical information of the patients

Parameter	Transthecal approach (n=9)	Conservative approach (n=12)	P-value
Sex, male, n (%)	3(33.3)	5(41.7)	1.000*
Age, years, mean \pm SD	47.78 \pm 19.23	44.17 \pm 14.01	0.624 [†]
Pathology, n (%)			1.000*
stenosis	5(55.6)	8(66.7)	
vertebral fx	3(33.3)	3(25.0)	
discopathy	1(11.1)	1(8.3)	
Smoking, yes, n (%)	2(22.2)	3(25.0)	1.000*
BMI, mean \pm SD	26.83 \pm 4.40	27.50 \pm 3.38	0.695 [†]

Abbreviations: SD, standard deviation; FX, fracture; BMI, body mass index

The result from the * χ^2 test; [†] independent sample t test

Table 2. Comparison of the postoperative complications and clinical outcomes in patients undergoing the two surgical approaches for anterior dural tear

Parameter	Transthecal approach (n=9)	Conservative approach (n=12)	P-value
Pseudomeningocele, yes, n (%)	0(0.0)	5(41.7)	0.045* [§]
Infection, yes, n (%)	1(11.1)	3(25.1)	0.603*
Rootlet herniation, yes, n (%)	0(0.0)	0(0.0)	
Pneumocephalus, yes, n (%)	0(0.0)	2(16.7)	0.486*
CSF leakage, yes, n (%)	1(11.1)	9(75.0)	0.008* [§]
Headache, yes, n (%)	2(22.2)	8(66.7)	0.080*
Meningitis, yes, n (%)	0(0.0)	4(33.3)	0.104*
Surgery duration, hour, mean \pm SD	3.78 \pm 0.58	2.89 \pm 0.64	0.004 [†] [§]
LOH, day, median (IQR)	6[4.5-7]	12[8-14.75]	0.002 [†] [§]

Abbreviations: SD, standard deviation; LOH, length of hospitalization; IQR, interquartile range

The result from the * χ^2 test, [†] independent sample t test, or [‡] Mann–Whitney U test

[§] significant at the 0.05 level

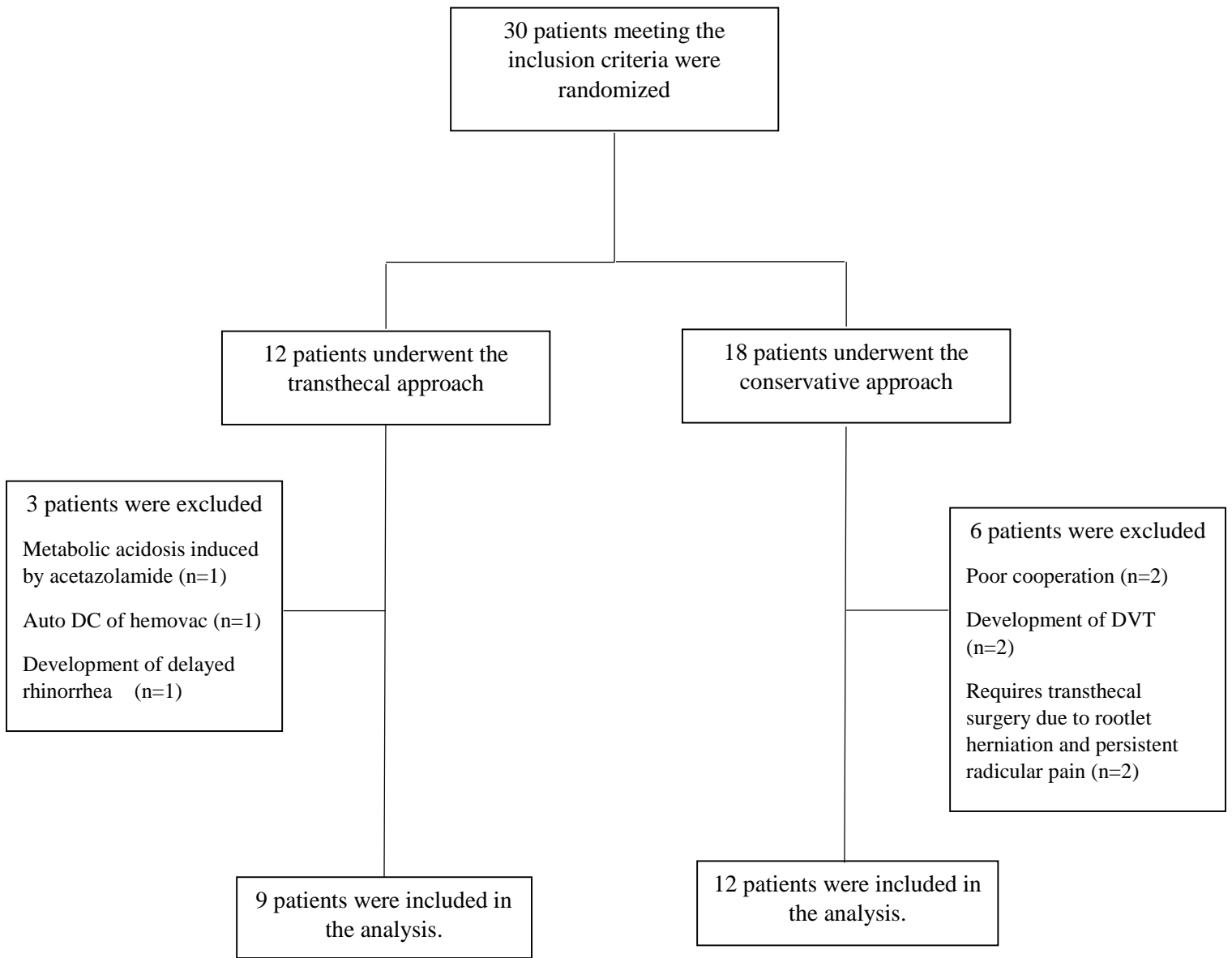


Figure 1. The flowchart of the study participants

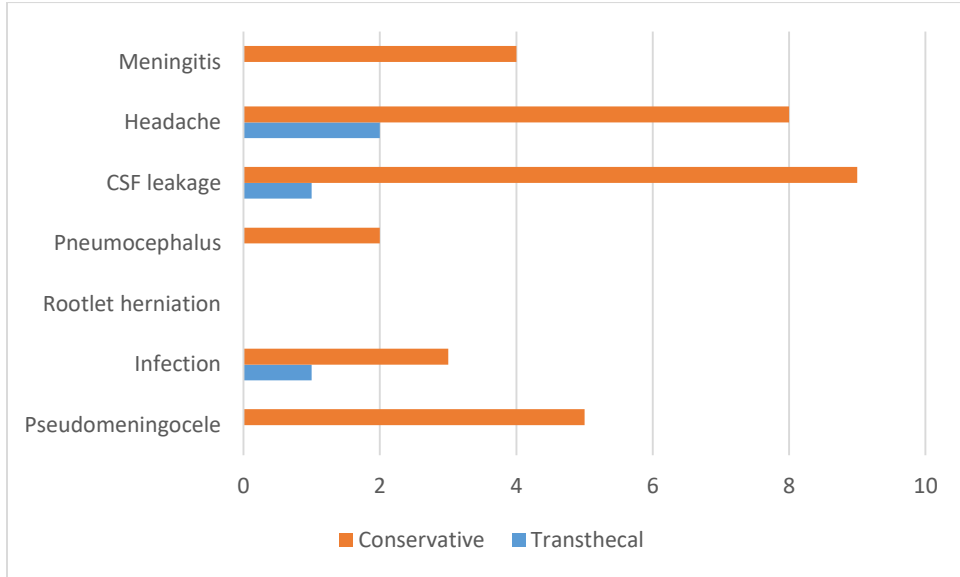


Figure 2. The clustered bar chart used to compare postoperative complications across patients undergoing the two surgical approaches for anterior dural tear

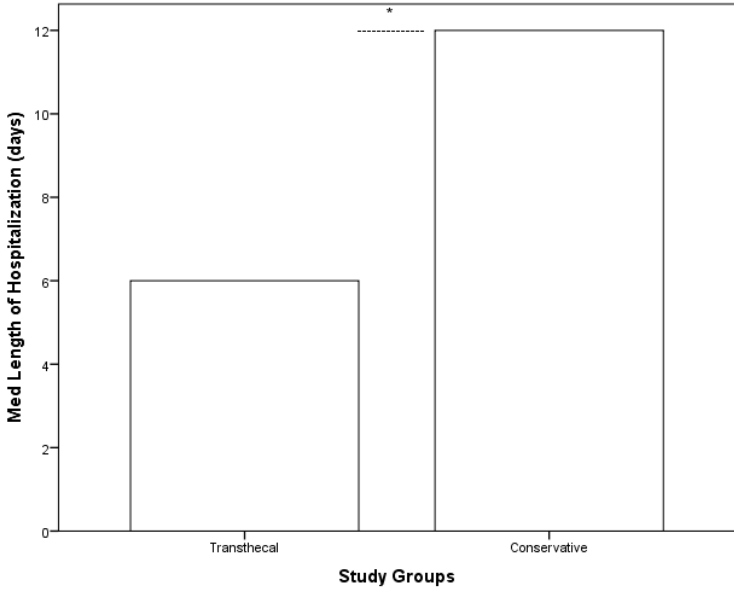


Figure 3. The bar graph showing the significant difference between the median of hospital stay for patients undergoing the two surgical approaches for anterior dural tear
* significant at the 0.05 level, resulting from the Mann-Whitney U test